

sTn is a Novel Biomarker for Type I Endometrial Carcinoma*

AN Yun-He^{1)**}, ZHANG Hao-Feng^{2)**}, SUN Min²⁾, ZHANG Jun^{2)***}, CHEN Xiu-Qin³⁾, CHEN Dong⁴⁾,
LU Di¹⁾, FENG Jing¹⁾, YANG Dong-Ling¹⁾, SONG Li-Na¹⁾, YAN Xi-Yun^{1)***}

¹⁾ Key Laboratory of Protein and Peptide Pharmaceutical, National Laboratory of Biomacromolecules, CAS-University of Tokyo Joint Laboratory of Structural Virology and Immunology, Institute of Biophysics, Chinese Academy of Sciences, Beijing 100101, China;

²⁾ Department of Obstetrics and Gynecology, Beijing Anzhen Hospital, Capital Medical University, Beijing 100029, China;

³⁾ Department of Obstetrics and Gynecology, The Fifth Affiliated Hospital of Zhengzhou University, Zhengzhou 450000, China;

⁴⁾ Department of Pathology, Beijing Anzhen Hospital, Capital Medical University, Beijing 100029, China)

Abstract Sialyl-Tn (sTn) is a tumor-associated carbohydrate antigen overexpressed in many carcinomas. But whether it is expressed in neoplastic human endometrium is controversial. Here we screened 111 clinical samples including 82 endometrial cancers, 16 atypical hyperplastic and 13 normal endometria, by immunohistochemistry using a novel anti-sTn antibody, namely 3P9. Our results showed that the expression of sTn in the endometrial carcinoma was significantly higher (76%) than that in normal tissues (31%) ($P < 0.01$) and in atypical hyperplasia (44%) ($P < 0.05$). Importantly, we found that sTn expression in type I carcinoma (80%) was obviously higher than that in type II (45%) ($P < 0.05$). These results suggested that sTn may be a biomarker for endometrial carcinoma, especially for type I carcinoma. Moreover, we observed that sTn expression was increased with the decline of tumor histological grade ($P < 0.05$), indicating that sTn was associated with a favorable prognosis in endometrial carcinoma.

Key words sialyl-Tn, anti-sTn antibody 3P9, endometrial carcinoma, immunohistochemistry

DOI: 10.3724/SP.J.1206.2012.00185

Endometrial carcinoma is the most common female pelvic malignancy. Based on the hormone level in tumorigenesis, endometrial carcinoma is subdivided into two major types: type I (estrogen-related) and type II (estrogen-unrelated) [1]. The 80% ~ 90% of endometrial cancers are type I which mainly comprises endometrioid carcinoma. The other 10% ~ 20% of endometrial cancer are type II tumors which are non-endometrioid subtypes, such as serous carcinoma, clear cell carcinoma and undifferentiated carcinoma [2]. Comparing with poorly differentiated type II carcinoma, type I are generally well- to moderately- differentiation with better prognosis.

To date, no characterized marker has been validated for the diagnosis of endometrial cancer. A number of studies have examined gene expression profiles for classifying uterine cancers. Mutations in K-ras and β -catenin oncogenes were found in type I

cancers. By contrast, type II cancers were associated with P53 gene mutations and Her-2/neu overexpression [3]. Nevertheless, none of these potential biomarkers has been validated nor reached the clinical practice. So, new biomarkers for prognosis and classification of endometrial cancer are needed.

*This work was supported by grants from The National Science and Technology Major Project (2012ZX10002009-016), National Basic Research Program of China (2009CB521704, 2011CB915502) and The National Natural Science Foundation of China (91029732).

**These authors contributed equally to this work.

***Corresponding author.

YAN Xi-Yun. Tel: 86-10-64888583, Fax: 86-10-64888584

E-mail: yanxy@sun5.ibp.ac.cn

ZHANG Jun. Tel: 86-10-64456686, Fax: 86-10-64456302

E-mail: zhang1126@yahoo.com.cn

Received: April 16, 2012 Accepted: May 15, 2012

Sialyl-Tn(sTn) is a simple mucin-type carbohydrate antigen. Abnormal expression of sTn is due to the premature sialylation of the core carbohydrate structure Gal-NAc α 1-O-Ser/Thr (Tn antigen), which stops further elongation of the oligosaccharide chains^[4]. Overexpression of sTn at the surface of cancer cells has been widely reported in several epithelial cancers such as gastric^[5], pancreatic^[6], colorectal^[7], ovarian^[8] and breast cancers^[9]. And the overexpression of sTn is related to tumor grade, invasion, metastasis and overall survival of the patients^[10-12]. However, data on the expression of sTn in normal and neoplastic conditions of human endometrium are scarcely available. Though some authors studied the sTn expression in endometrial cancer, the results were controversial. For instance, Inoue *et al*^[13] and Semczuk *et al*^[14] reported that sTn was widely expressed in most endometrial cancer and restricted in normal and hyperplastic human endometrium. However, Numa and co-workers^[15] reported that sTn was not expressed in endometrial carcinoma.

In this study, we employed 111 clinical samples containing 82 endometrial carcinoma, 16 atypical hyperplastic and 13 normal tissues to clarify this issue using a novel anti-sTn antibody mAb 3P9 by immunohistochemistry. Our data showed that not all the endometrial carcinoma highly expressed sTn antigen. In type I endometrial carcinoma, 80% was positive, which was significantly higher than that in type II endometrial carcinoma (45%). This might give a reasonable explanation for the controversial reports since they did not distinguish the differences of type I and type II. In all, our study suggested that sTn may be a biomarker for endometrial carcinoma, especially for type I carcinoma. It could be used for the classification of patients into categories with different risk of recurrence to better tailor adjuvant treatment. The type I and/or type II should be properly evaluated in a prospective randomized trial in management of endometrial carcinoma. Simultaneously, this study supplied a novel reagent, namely mAb 3P9, to execute these functions above.

1 Materials and methods

1.1 Antibodies and cells

Anti-sTn antibody mAb 3P9 was generated by our lab, anti-sTn mAb TKH2 was provided by Prof. Steven Itzkowitz (Mount Sinai School of Medicine, New York, USA), anti-sTn mAb B72.3 (Invitrogen)

was purchased, LSC^{sTn+} and LSB^{sTn-} cells^[16] were also provided by Prof. Steven Itzkowitz, MDA-MB-231^{sTn+} and MDA-MB-231^{sTn-} cells^[17] were provided by Prof. Philippe Delannoy (Université des Sciences et Technologies de Lille, France), BSM (bovine submaxillary gland mucin) and periodic acid were Sigma products, NaOH was purchased from Beijing Chemical Reagents Company (China).

1.2 Clinical samples and information

Eighty-two endometrial cancer tissues were supplied by Department of Obstetrics and Gynecology, The Fifth Affiliated Hospital of Zhengzhou University and Department of Obstetrics and Gynecology, Beijing Anzhen Hospital, Capital Medical University.

The information of patients: (1) Mean patient age was 57 years (range 23 ~ 84). None of the patients had received chemo-, hormone-, or radio-therapy before surgery. Surgical pathologic staging of cancer was done according to the FIGO criteria in 2009. (2) Fifty-two patients (63%) had stage I tumor, eighteen patients (22%) had stage II tumor, eleven patients (14%) had stage III tumor and one patient (1%) had stage IV tumor. (3) Fifteen (18%) neoplasms were well-differentiated (G1), forty (49%) were moderately-differentiated (G2), and twenty-seven (33%) were poorly-differentiated (G3). The histological features were determined according to the WHO staging system. (4) The information of clinicopathological subtypes was that seventy(87%) tissues of endometrioid carcinoma as type I cancer, nine (11%) tissues of uterine papillary serous carcinoma and two (2%) clear cell carcinoma as type II cancer. (5) There was no myometrial invasion of the neoplasm in eight (10%) cases; invasion of less than half of the myometrium was noted in forty-six (56%) cases, and invasion beyond half of the myometrium in twenty-eight (34%). (6) Thirteen normal endometrial specimens were collected from the hysterectomy in the non-cancer patients (3 cases of multiple uterine leiomyomas and 10 cases of adenomyosis) and sixteen atypical hyperplastic endometrial specimens were also evaluated. Informed written consent and ethic approval were obtained by the institutional biomedical research ethics committee of the Institute of Biophysics, Chinese Academy of Sciences before the specimen collection.

1.3 Generation of monoclonal antibody

Human colorectal adenocarcinoma SW1116 cells (5×10^6) was injected intraperitoneally with Freund

complete adjuvant into 6-week-old BALB/c mice and boosted 3 times with Freund incomplete adjuvant, and then their spleens were taken for hybridoma preparation as described^[18].

1.4 Indirect ELISA

The indirect enzyme-linked immunosorbent assay (ELISA) was used to select antibodies binding to BSM. BSM was coated on 96-well plates overnight in 4°C. Plates were washed 3 times in phosphate-buffered saline (PBS) and then incubated with periodic acid (2%) for 1 h at 37°C, NaOH (0.2%) for 10 min at room temperature or PBS as control. After washing with PBS, plates were blocked with 5% bovine serum albumin (BSA) for 1 h at 37°C and then incubated with mAb 3P9. The bound antibodies were detected by incubation with HRP (horseradish peroxidase)-conjugated anti-mouse antibody at 25°C for another hour. After careful washing, 3, 3', 5, 5'-tetramethylbenzidine (TMB) (Sigma, Deisenhofen, Germany) was added as substrate for HRP and the color reaction was measured at 450 nm with a Bio-Rad ELISA reader (Richmond, CA).

1.5 Competitive inhibitory ELISA

Plates were coated with 2 mg/L BSM and blocked with 5% BSA. After adding primary antibody 3P9, the antigen BSM was competitively binding to 3P9 in a concentration gradient of 0, 0.02, 0.04, 0.08, 0.16, 0.32, 0.64, 1.28, 2.56 and 5.12 mg/L, while 5 mg/L anti-sTn antibody B72.3/TKH2 was added together for 2 h at room temperature. Washing was performed, sequentially HRP-conjugate goat anti-mouse IgM antibody (Sigma) was also supplied for 1 h at room temperature. Repeating the washing steps and TMB substrate was added to each well. Color reaction was measured at 450 nm with a Bio-Rad ELISA reader (Richmond, CA).

1.6 Flow cytometric analysis

Detached cells were incubated with primary antibodies, 3P9 or IgM as control, on ice for 40 min. After washing, the cells were incubated with FITC-conjugated secondary antibodies (Invitrogen) on ice for 30 min, then washed and analyzed using FACSCalibur flow cytometry system (Becton Dickinson).

1.7 Immunohistochemistry

The 4 μm sections were obtained from each paraffin-block. The slides were deparaffinized by incubating twice in xylene for 30 min at a time and then incubated in 100%, 90%, 70%, 50%, and

30% ethanol successively for 5 min in each ethanol solution. Then the sections were incubated with 0.3% H₂O₂ in methanol for 30 min to quench endogenous peroxidases and boiled for 30 min in 10 mmol/L citrate buffer (pH 6.0) to expose the epitope completely. Let the slides cool down naturally in the buffer. Sequentially, the sections were blocked with 5% goat serum in PBS at 37°C for 1 h and then incubated with primary anti-sTn monoclonal antibody 3P9 overnight at 4°C. The negative control slides were kept in PBS under the same conditions. Appropriate horseradish peroxidase conjugated second antibodies were applied to the sections. After every incubation step, the sections were washed with PBS three times. Freshly prepared 3, 3'-diaminobenzidine tetrahydrochloride (Sigma, Deisenhofen, Germany) was added to the sections as substrate. The slides were finally counterstained with Meyer's hematoxylin and mounted when dry. The grading of antigen immunoreactivity was classified into 5 groups according to the percentage of reactive cells: 0 (<5%), 1+ (5% to <10%), 2+ (10% to <25%), 3+ (25% to <50%), and 4+ (50% or more). More than 500 cells were counted on each slide.

1.8 Statistical analysis

Statistical analyses were carried out by using the statistics package SPSS 16.0. Fisher's exact test or the χ -square test was used to analyze the relationship between sTn reactivity and the clinicopathological variables of cancer, whereas, the relationship between patient age and the sTn expression was analyzed applying Spearman's rank correlation test. $P < 0.05$ was considered to indicate statistical significance.

2 Results

2.1 Generation and characterization of anti-sTn antibody

We generated hundreds of hybridomas in this study. They were subjected to antibody screen by a method of ELISA and immunohistochemistry with tumor and normal tissues (data not shown). One of these clones, named 3P9, which produced an IgM/ κ and could specifically bind to human endometrial cancer tissues but not to normal tissues, was chosen for further characterization.

Based on the observations in immunohistochemistry, we speculate that the antigen recognized by mAb 3P9 is probably related to mucins, which are the main secretory products of glandular epithelium.

Considering mucins being highly glycosylated and usually undergoing aberrant glycosylation during the development of malignancy, we firstly tested if the mAb 3P9 antigen is a glycan. BSM (bovine submaxillary mucin) is employed to validate our speculation because BSM antigen is a highly glycosylated and widely used mucin-type protein. Oxidation of the carbohydrate chain with 2% periodic acid severely impaired the binding of mAb 3P9 to BSM, whereas 0.2% NaOH treatment did not influence the recognition (Figure 1a). This indicated that the epitope identified by mAb 3P9 was located on the carbohydrate side chain but not the peptide backbone of the glycoprotein.

Considering sialylated Tn antigen was frequently expressed in many epithelial cancers, we performed competitive inhibition ELISA and found that the binding capacity of mAb 3P9 to BSM was markedly inhibited by well-known anti-sTn antibody B72.3 and

TKH2 in a dose-dependent manner (Figure 1b).

Moreover, a pair of well-established cell lines, namely LSC^{sTn+} and LSB^{sTn-}, was employed to determine the antigen of mAb 3P9 by FACS. LSC^{sTn+} cells express sTn and were stained by mAb 3P9, while LSB^{sTn-} cells, which have the exactly same genetic background as LSC^{sTn+} but do not express sTn, could not be stained by mAb 3P9 (Figure 1c). In addition, another pair of breast cancer cell lines, namely MDA-MB-231^{sTn+} and MDA-MB-231^{sTn-}, was also employed to determine the antigen of mAb 3P9. They were generated by transfection with ST6GalNAc-I and mock vector into MDA-MB-231 cells respectively^[17], which is different from the method of gaining LSC^{sTn+}/LSB^{sTn-} cells^[16]. MDA-MB-231^{sTn+} cells were stained by mAb 3P9, but MDA-MB-231^{sTn-} cells could not be stained (Figure 1c). These data finally ensured that mAb 3P9 specifically recognizes the carbohydrate structure of sTn.

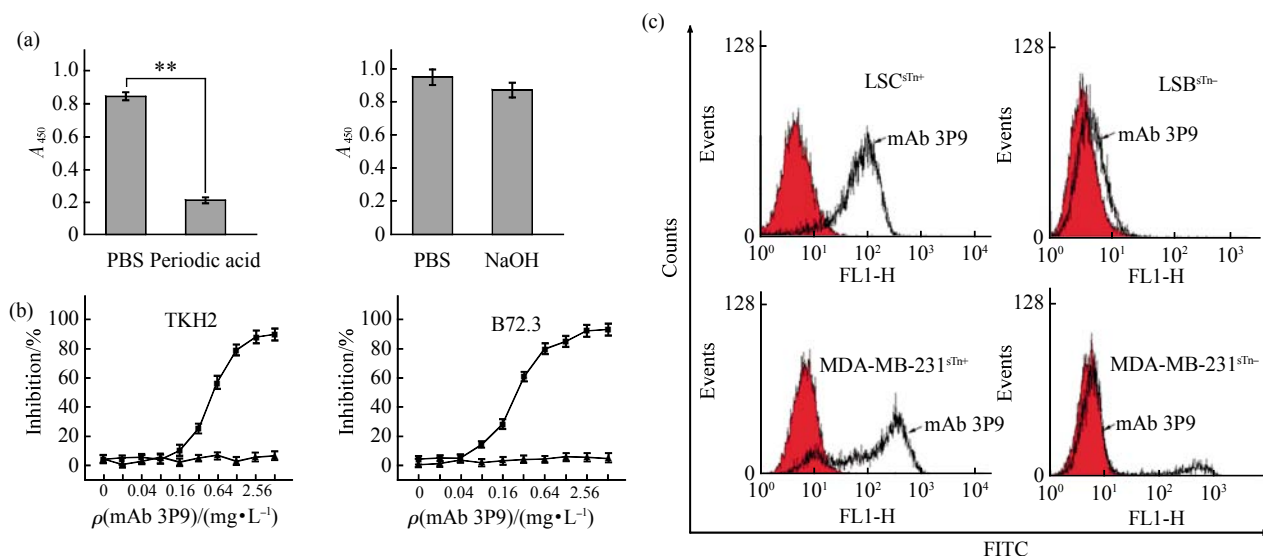


Fig. 1 Identification the mAb 3P9 antigen

(a) BSM proteins coated on the plate were treated with periodic acid (2%) for 1 h at 37°C, NaOH (0.2%) for 10 min at room temperature or PBS as control and then reacted with mAb 3P9 in an ELISA assay. $**P < 0.01$. (b) Binding of different concentrations of mAb 3P9 to BSM was tested in a competitive ELISA assay in the presence of anti-sTn mAb TKH2 or mAb B72.3. \blacktriangle — \blacktriangle : mIgM; \blacksquare — \blacksquare : mAb 3P9. (c) Flow cytometric analysis of the binding of mAb 3P9 to LSC^{sTn+}/LSB^{sTn-} or MDA-MB-231^{sTn+}/MDA-MB-231^{sTn-} cells.

2.2 sTn highly expressed in endometrial carcinoma

To clarify whether sTn was highly expressed in endometrial carcinoma, we used mAb 3P9 to screening 111 clinical samples including 71 endometrioid carcinoma as type I cancer, 9 uterine papillary serous carcinoma and 2 clear cell carcinoma as type II cancer,

16 atypical hyperplasia and 13 normal tissues. Our study showed there was no (0, <5%) or weak (1+, 5% to <10%) sTn immunostaining in most normal and atypical hyperplastic tissues (Figure 2 g~l). Weak sTn reactivity was observed in 4/13 (31%) normal slides and 7/16 (44%) atypical hyperplastic slides. And the

staining was mostly restricted in cell membrane (Figure 2g, k). However, the frequency rate of positive sTn tests was 80% (57 of 71) for endometrioid carcinoma, 44% (4 of 9) for uterine papillary serous carcinoma and 50% (1 of 2) for clear cell carcinoma. In all, the positive expression of sTn antigen in endometrial carcinoma was 76% (62 of 82), which was significantly higher than that in normal tissues (31%) ($P = 0.003$) and that in atypical hyperplastic tissues (44%) ($P = 0.024$). To be noticed, the

statistically significant difference was found between atypical hyperplasia and type I endometrial cancer (endometrioid carcinoma) ($P=0.009$) but there was no difference between atypical hyperplasia and type II cancer (papillary serous carcinoma and clear cell carcinoma) ($P=1.000$) (Table 1). Positive staining was observed throughout the cytoplasm of the glandular cancer cells and in an intraluminal mucus(Figure 2a~d), not restricted in cell membrane.

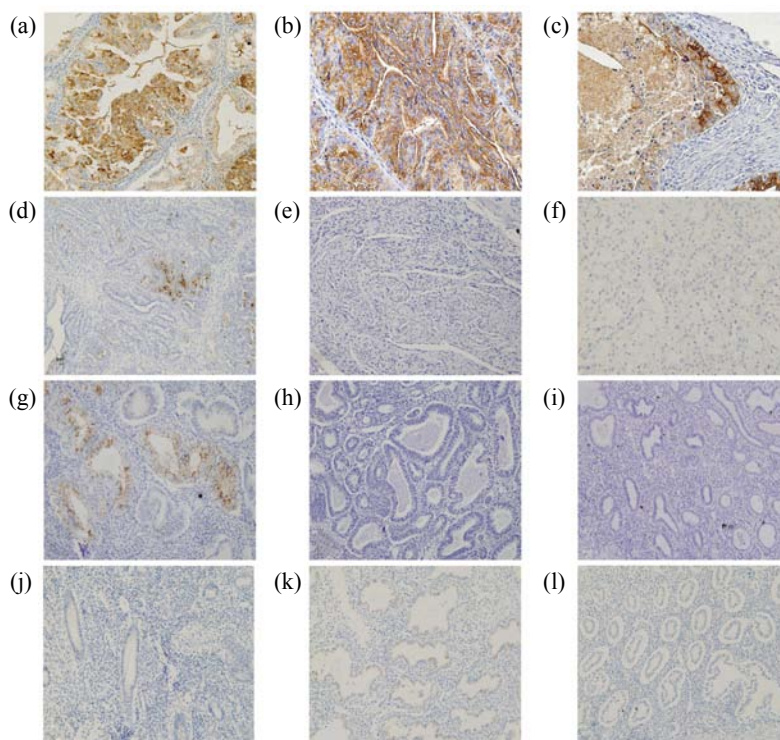


Fig. 2 Immunoreactivity of sTn in endometrial carcinoma

(a~c) Type I carcinoma. (d~f) Type II carcinoma. (g~i) Atypical hyperplasia. (a) Endometrioid carcinoma I stage. (b) Endometrioid carcinoma II stage. (c) Endometrioid carcinoma III stage. (d) Uterine papillary serous carcinomas II stage. (e) Uterine papillary serous carcinomas I stage. (f) Clear cell carcinomas II stage. Magnification is 100 folds.

Table 1 sTn expression in normal and pathological conditions of human endometrium

Samples	Positive/Total	Intensity of immunostaining ¹⁾					$P^2)$
		0	1+	2+	3+	4+	
Normal endometrium(31%)	4/13	9	3	1	0	0	$P1=0.003$
Atypical hyperplasia (44%)	7/16	9	2	2	3	0	$P2=0.024$
Neoplastic endometrium(76%)	62/82	20	5	15	13	29	
Endometrioid carcinoma(80%)	57/71	14	5	15	9	28	$P3=0.009$
Papillary serous carcinoma(44%)	4/9	5	0	0	3	1	$P4=1.000$
Clear cell carcinoma(50%)	1/2	1	0	0	1	0	

Number in parentheses is the positive rate of sTn expression. ¹⁾ sTn immunoreactivity: 0(< 5%); 1+(5% to < 10%); 2+(10% to < 25%); 3+(25% to < 50%); 4+(50% or more). ²⁾ $P1$ represents the difference between the normal and neoplastic endometrium, Pearson Chi-square test; $P2$ represents the difference between the atypical hyperplasia and the neoplastic endometrium, Pearson Chi-square test; $P3$ represents the difference between the atypical hyperplasia and the endometrioid adenocarcinoma, Fisher's exact test; $P4$ represents the difference between the atypical hyperplasia and the papillary serous and clear cell carcinoma, Fisher's exact test.

2.3 sTn expression correlated with histological grade and type I carcinoma

The expression of sTn in endometrial cancer correlated with histological grade ($P=0.021$) and clinicopathologic subtype ($P=0.023$). But no significant correlation was shown between sTn expression and other clinicopathologic features, such as patient age ($P=0.559$), clinical stage ($P=0.198$) and myometrial invasion depth ($P=0.887$). The expression of sTn decreased with the degree of tumor

differentiation (Table 2). When the tumor was poorly-differentiated (G3), the positive rate of sTn expression was 59%, which was significantly lower than that in well- (G1) and moderately- (G2) differentiated tumors. In addition, The frequency of sTn expression in type I (80%) carcinoma was obviously higher than that in type II (45%) carcinoma. There was a significant difference between type I and type II endometrial carcinoma (Table 2).

Table 2 Correlation between sTn expression and clinicopathological parameters in endometrial cancer

Parameter	n	sTn		P
		Positive	Negative	
Patient age (years)				
< 50	13	9 (69%)	4 (31%)	0.559 ¹⁾
≥ 50	69	53(77%)	16(23%)	
FIGO Stage				
I - II	70	54 (74%)	16 (26%)	0.198 ¹⁾
III -IV	12	8 (67%)	4 (33%)	
Histological grade				
G1	15	11 (73%)	4 (27%)	0.021 ¹⁾
G2	40	35 (87%)	5 (13%)	
G3	27	16 (59%)	11 (41%)	
Depth of myometrial				
< 1/2	54	40 (74%)	14 (26%)	0.887 ¹⁾
> 1/2	28	22 (79%)	6 (21%)	
Clinicopathologic subtype				
Type I cancer	71	57 (80%)	14 (20%)	0.023 ¹⁾
Type II cancer	11	5 (45%)	6 (55%)	

¹⁾Pearson Chi-square test, ²⁾Spearman's rank correlation test.

3 Discussion

Although the sTn overexpression has been reported in many epithelia-derived cancers^[19], the study of sTn expression in normal and pathological conditions of human endometrium was controversial. Since endometrial carcinoma has been subdivided into two major types, type I and type II, and they are totally different in tumor histological subtype and clinical behavior, so we speculated that the conflicting results in the past may be due to not distinguishing the two type cancers in the selection of study subjects. Here, we employed 71 type I cancers (endometrioid carcinoma) and 11 type II cancers (papillary serous

carcinoma and clear cell carcinoma) to address this issue. Our results firstly demonstrated that the expression of sTn was statistically significantly associated with type I endometrial carcinoma rather than with type II carcinoma, which confirmed our hypothesis. The frequency rate of sTn expression in type I carcinoma (80%) was obviously higher than that in type II carcinoma (45%). All of these results suggested that sTn antigen is a new potential biomarker and therapeutic target in type I carcinoma.

Moreover, our results showed that the expression rate of sTn was 31% in normal tissues, 44% in atypical hyperplastic endometrium and 76% in endometrial carcinoma, which indicated that sTn was involved in

endometrial carcinogenesis and progression. Besides the significantly difference on sTn expression between endometrial carcinoma and normal tissue ($P=0.003$), importantly, the significant difference also existed between the atypical hyperplasia and type I carcinoma ($P=0.009$) rather than type II carcinoma ($P=1.000$). Atypical endometrial hyperplasia represents the precursor of endometrioid carcinoma (type I). It is difficult to distinguish the two lesions in clinicopathologic diagnosis because they are similar in histopathological morphology, often present concurrently and in topographic proximity in hysterectomy specimens^[1]. Here our study supplied a novel marker to identify the difference between atypical hyperplasia and type I cancer, and thereby improve the diagnostic accuracy.

We found there was a statistically significant association between sTn expression and histological grade. As shown in the Table 2, the expression of sTn decreased with the degree of tumor differentiation. The positive rate of sTn expression in poorly- differentiated carcinoma (G3) was significantly lower than that in well- (G1) and moderate- (G2) differentiated tumors ($P < 0.05$), which was consistent with previous study by Semczuk *et al.* The correlation of sTn with histological grade and type I carcinoma which characterized with good clinical behavior suggested that sTn may be associated with a favorable prognosis in endometrial carcinoma.

Additionally, we noticed that in normal and hyperplastic tissues, the immunostaining of sTn was weak, and the reactivity was mostly restricted in cell membrane. But in endometrial carcinomas, the positive staining was observed throughout the cytoplasm of the glandular cancer cells and in an intraluminal mucus, not restricted in cell membrane. This result seems to be reasonable because during carcinogenesis, the normal topology and polarity of epithelial cells both change markedly. The aberrantly glycosylated mucins, such as truncated carbohydrate chain (Tn, sTn), expressed on the whole cell surface, could be re-arranged or shed into the bloodstream^[20].

All of these results were executed by the novel anti-sTn antibody 3P9. It can effectively identify the sTn expression in endometrial cancer and distinguish the expression differences in histological grade and type I /type II cancer. So mAb 3P9 was a new useful tool for diagnosis and therapy in endometrial cancer.

In conclusion, we generated a novel anti-sTn

antibody 3P9 to study the sTn expression. Our study demonstrated that sTn highly expressed in type I endometrial cancer and there was a significant difference between endometrioid carcinoma and atypical hyperplastic endometrium. Moreover, sTn expression was correlated with histologic grade of endometrial carcinoma. All of these results indicated that sTn has potential to be used as a diagnostic aid in the surgical pathology of the uterine neoplasia and to become a new therapeutic target, especially for type I endometrial carcinoma.

Acknowledgments We thank ZHENG Rui-Min and ZHAO Xu-Dong of the IBP Core Facilities Centre for technical assistance.

References

- [1] Sherman M E. Theories of endometrial carcinogenesis: A multidisciplinary approach. *Mod Pathol*, 2000, **13**(3): 295–308
- [2] Gregg S, Mangili G, Scaffa C, *et al.* Uterine papillary serous, clear cell, and poorly differentiated endometrioid carcinomas: a comparative study. *Int J Gynecol Cancer*, 2011, **21**(4): 661–667
- [3] Dobrzycka B, Terlikowski S J. Biomarkers as prognostic factors in endometrial cancer. *Folia Histochem Cytobiol*, 2010, **48**(3): 319–322
- [4] Sewell R, Backstrom M, Dalziel M, *et al.* The ST6GalNAc-I sialyltransferase localizes throughout the Golgi and is responsible for the synthesis of the tumor-associated sialyl-Tn O-glycan in human breast cancer. *J Biol Chem*, 2006, **281**(6): 3586–3594
- [5] Conze T, Carvalho A S, Landegren U, *et al.* MUC2 mucin is a major carrier of the cancer-associated sialyl-Tn antigen in intestinal metaplasia and gastric carcinomas. *Glycobiology*, 2010, **20**(2): 199–206
- [6] Kim G E, Bae H I, Park H U, *et al.* Aberrant expression of MUC5AC and MUC6 gastric mucins and sialyl Tn antigen in intraepithelial neoplasms of the pancreas. *Gastroenterology*, 2002, **123**(4): 1052–1060
- [7] Ogata S, Koganty R, Reddish M, *et al.* Different modes of sialyl-Tn expression during malignant transformation of human colonic mucosa. *Glycoconj J*, 1998, **15**(1): 29–35
- [8] Van Elssen C H, Frings P W, Bot F J, *et al.* Expression of aberrantly glycosylated Mucin-1 in ovarian cancer. *Histopathology*, 2010, **57**(4): 597–606.
- [9] Cazet A, Julien S, Bobowski M, *et al.* Tumour-associated carbohydrate antigens in breast cancer. *Breast Cancer Res*, 2010, **12**(3): 204
- [10] Cazet A, Julien S, Bobowski M, *et al.* Consequences of the expression of sialylated antigens in breast cancer. *Carbohydr Res*, 2010, **345**(10): 1377–1383
- [11] Magnani J L. The discovery, biology, and drug development of sialyl Lea and sialyl Lex. *Arch Biochem Biophys*, 2004, **426**(2):

- 122-131
- [12] Paschos K A, Canovas D, Bird N C. The engagement of selectins and their ligands in colorectal cancer liver metastases. *J Cell Mol Med*, 2010, **14**(1-2): 165-174
- [13] Inoue M, Ogawa H, Tanizawa O, *et al.* Immunodetection of sialyl-Tn antigen in normal, hyperplastic and cancerous tissues of the uterine endometrium. *Virchows Arch A Pathol Anat Histopathol*, 1991, **418**(2): 157-162
- [14] Semczuk A, Paszkowska A, Miturski R, *et al.* Sialosyl-Tn expression in normal and pathological conditions of human endometrium. An immunohistochemical study. *Pathol Res Pract*, 2002, **198**(9): 589-595
- [15] Numa F, Tsunaga N, Michioka T, *et al.* Tissue expression of Sialyl Tn antigen in gynecologic tumors. *J Obstet Gynaecol (Tokyo 1995)*, 1995, **21**(4): 385-389
- [16] Brockhausen I, Yang J, Dickinson N, *et al.* Enzymatic basis for sialyl-Tn expression in human colon cancer cells. *Glycoconjugate J*, 1998, **15**(6): 595-603
- [17] Julien S, Krzewinski-Recchi M A, Harduin-Lepers A, *et al.* Expression of sialyl-Tn antigen in breast cancer cells transfected with the human CMP-Neu5Ac: GalNAc alpha2,6-sialyltransferase (ST6GalNAc I) cDNA. *Glycoconj J*, 2001, **18**(11-12): 883-893
- [18] Kohler G, Milstein C. Continuous cultures of fused cells secreting antibody of predefined specificity. *Nature*, 1975, **256**(5517): 495-497
- [19] Heimburg-Molinaro J, Lum M, Vijay G, *et al.* Cancer vaccines and carbohydrate epitopes. *Vaccine*, 2011, **29**(48): 8802-8826
- [20] Hollingsworth M A, Swanson B J. Mucins in cancer: protection and control of the cell surface. *Nat Rev Cancer*, 2004, **4**(1): 45-60

糖抗原 sTn 是 I 型子宫内膜癌的新型标记物 *

安云鹤^{1)**} 张豪锋^{2)**} 孙敏²⁾ 张军^{2)***} 陈秀琴³⁾ 陈东⁴⁾
卢迪¹⁾ 冯静¹⁾ 杨冬玲¹⁾ 宋丽娜¹⁾ 阎锡蕴^{1)***}

¹⁾ 中国科学院生物物理研究所蛋白质与多肽药物重点实验室, 结构病毒学与免疫学中日联合实验室, 北京 100101;

²⁾ 首都医科大学附属北京安贞医院妇产科, 北京 100029;

³⁾ 郑州大学第五附属医院妇产科, 郑州 450000; ⁴⁾ 首都医科大学附属北京安贞医院病理科, 北京 100029)

摘要 Sialyl-Tn(sTn)是肿瘤相关糖抗原的一种, 在多种上皮来源的肿瘤组织中都存在 sTn 的过表达. 但是, 关于 sTn 在子宫内膜癌中的表达情况目前研究得很少, 而且仅有的报道也互相矛盾. 为了阐明这一问题, 我们选取了 111 例临床样本, 其中包括 82 例子官内膜癌, 16 例非典型增生内膜, 13 例正常内膜, 利用免疫组化的方法分析了 sTn 的表达情况. 结果表明, sTn 在子宫内膜癌中高表达, 但仅限于 I 型子宫内膜癌(80%), 而在 II 型子宫内膜癌中表达率仅为 45%, 二者具有显著性差异($P < 0.05$). 这是我们首次报道 sTn 特异性与 I 型子宫内膜癌相关, 有利于解释过去前后不一的矛盾结果. 在非典型组织中, sTn 的表达率较正常组织高, 分别为 31%(正常组织)和 44%(非典型组织). 这说明 sTn 参与了子宫内膜癌的发生发展. 同时, 我们的结果表明, sTn 的表达与肿瘤的组织分级具有相关性, 其在高、中分化的肿瘤组织中表达率明显高于低分化的肿瘤组织. 这预示着 sTn 可能与子宫内膜癌的良好预后相关. 我们的研究为诊断 I 型子宫内膜癌提供了一个新的标记物和诊断试剂, 同时提示我们, 将来对于子宫内膜癌的研究, 有必要对 I 型子宫内膜癌和 II 型子宫内膜癌区别对待.

关键词 sTn, 抗 sTn 的单克隆抗体 3P9, 子宫内膜癌, 免疫组化

学科分类号 Q2, Q5

DOI: 10.3724/SP.J.1206.2012.00185

* 国家科技重大项目(2012ZX10002009-016), 国家重点基础研究发展计划(973)资助项目(2009CB521704, 2011CB915502), 国家自然科学基金资助项目(91029732).

** 共同第一作者.

*** 通讯联系人.

阎锡蕴. Tel: 010-64888583, Fax: 010-64888584, E-mail: yanxy@sun5.ibp.ac.cn

张军. Tel: 010-64456686, Fax: 010-64456302, E-mail: zhang1126@yahoo.com.cn

收稿日期: 2012-04-16, 接受日期: 2012-05-15